



PATIENT

Honey Jordano

PRESENTING CLINICAL SIGNS

History: Acute onset seizures v ataxia. Arrhythmia during echo.
Pertinent US results (EL 6/22/22): NSF with occ arrhythmia; AUS nsf

SPECIES

Canine

BREED

Boxer Mix

SEX

FS

AGE

1 year

WEIGHT

51

INTERPRETED BY

Maggie Machen Lamy,
DVM, DACVIM
(Cardiology)

IMAGING PERFORMED BY

HOLTER MONITOR FINDINGS AND RHYTHM ASSESSMENT

Time analyzed	23:29h
Mean heart rate	72bpm
Maximum heart rate	234bpm
Minimum heart rate	39bpm
VPCs	3 singles
APCs	0

Interpretation: Underlying normal sinus rhythm with apparently appropriate rate variation (no diary included). Three single VPCs are seen, which are essentially a normal finding for a 24 hour recording. Occasional escape beats while sleeping/bradycardic which is a normal response.

Rhythm diagnosis: Normal sinus rhythm with rare isolated VPCs (3).

RECOMMENDATIONS

Essentially normal recording. No significant extra-nodal tachycardias are noted, and no malignant arrhythmias identified. The HR is appropriate as compared to the time of day, although this cannot be confirmed without a diary. Finally, three single VPCs are noted, which is considered incidental in an otherwise healthy dog (up to 50-100 VPCs per 24 hours is normal in a Boxer). No pathology is seen here.

These findings would suggest arrhythmias during the echocardiogram may be incorrect (an ECG was not attached) or may reflect pathology not appreciated here. Regardless, a 1 year old Boxer with arrhythmogenic disease would be highly unlikely. It is more likely that primary neurologic/systemic issues are causing the clinical signs, and further evaluation is advised.

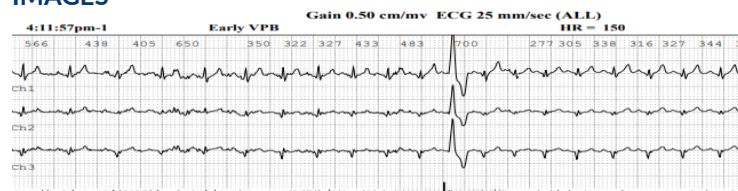
No medications are indicated at this time.

Recheck pending clinical progression. Holter/echo screening of this breed is typically recommended annually after 5 years of age, sooner if any further clinical signs are noted.

HOSPITAL NAME

Rockaway AH

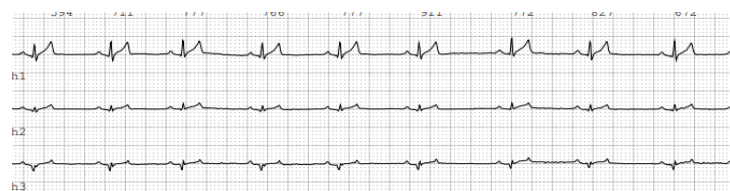
IMAGES



Single VPC

REFERRING VET

Dr. Maniar



NSR

INVOICE

25126

DATE

7/1/22



PATIENT

Honey Jordano

The information and recommendations provided are based on the images presented by the referring veterinarian. No evaluation can be communicated regarding pathology that was not visible in the image/video clips provided.

SPECIES

Canine

Thank you for this referral. If the clinical or image interpretation does not parallel your findings or if I can be of any further assistance please contact me.

BREED

Boxer Mix

Maggie Machen Lamy, DVM
Diplomate of the American College of Veterinary Internal Medicine (Cardiology)
info@sonopath.com

SEX

FS

AGE

1 year

WEIGHT

51

INTERPRETED BY

Maggie Machen Lamy,
DVM, DACVIM
(Cardiology)

**IMAGING
PERFORMED BY**

HOSPITAL NAME

Rockaway AH

REFERRING VET

Dr. Maniar

INVOICE

25126

DATE

7/1/22